

# Comprehensive Management of Ovarian Tumour-related Torsion: A Case Report

DEEPAKSHI GUPTA<sup>1</sup>, VARSHA KOSE<sup>2</sup>

CC BY-NC-ND

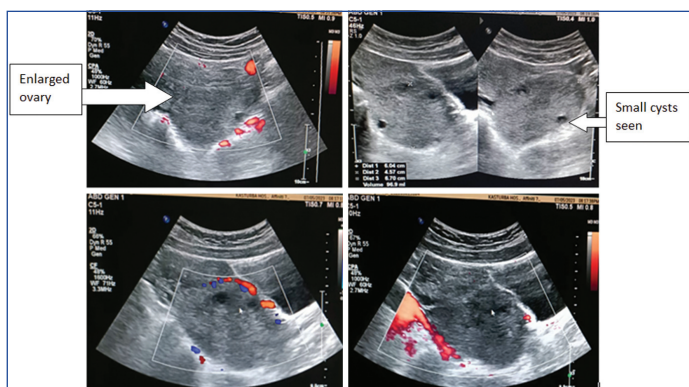
## ABSTRACT

Ovarian tumours are diverse and lead to rare yet critical complications such as torsion. The ovary twists on its own axis and compromises blood flow. Ovarian torsion is uncommon and has considerable risk in women of reproductive age. The present case report elucidates the intricate nature of ovarian tumours, particularly emphasising the rare yet critical complication of torsion, where the ovary twists, compromising blood flow. The presented case involves a 35-year-old multiparous woman with acute abdominal pain, vomiting, and elevated Cancer Antigen 125 (CA-125) levels, leading to the diagnosis of a left ovarian cyst with torsion via Ultrasonography (USG). The subsequent surgical intervention, involving exploratory laparotomy, successfully confirmed and addressed the issue, resulting in detorsion and cystectomy. Histopathological examination further identified a benign serous cystadenoma. The present case underscores the diagnostic challenges associated with ovarian tumour-related torsion, highlighting the importance of symptom analysis and diagnostic imaging for early recognition. It also emphasises the effectiveness of surgical intervention, showcasing varied treatment options, from cystectomy to detorsion, contingent on individual circumstances. The present case report stresses the imperative of a multidisciplinary approach involving gynaecologists, radiologists and surgeons for optimal outcomes in managing this complex condition.

**Keywords:** Abdominal pain, Benign serous cystadenoma, Exploratory laparotomy, Left ovarian cyst

## CASE REPORT

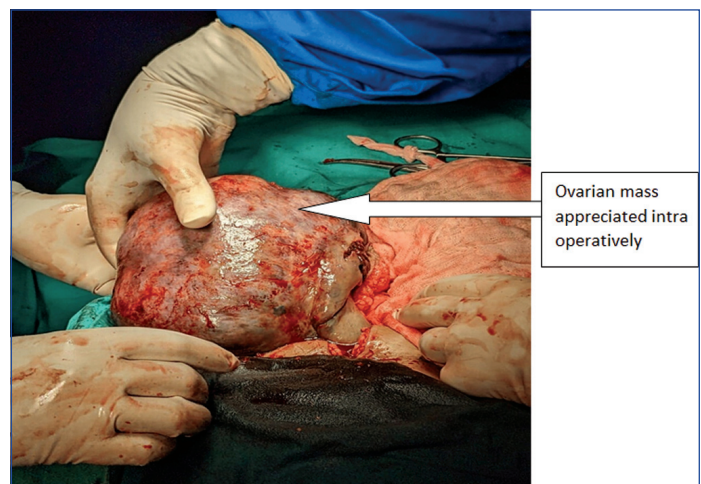
A 35-year-old multiparous woman presented with acute abdominal pain escalating in intensity and recurrent episodes of vomiting for three weeks. Her menstrual cycles were regular with average flow, no clots, or dysmenorrhea. The patient exhibited tachycardia, with an average pulse rate of 140 beats/minute. Diagnostic assessments revealed microcytic hypochromic anaemia (Haemoglobin: 9 g/dL), leucocytosis {Total Leucocyte Count (TLC): 15,190 cells/microlitre}, and an elevated CA-125 value of 75 U/mL. Pelvic Ultrasonography (USG) indicated a 16×16×10 cm<sup>3</sup>, 1 kg left ovarian cyst, strongly suggestive of an ovarian tumour with torsion. The abdominal and pelvic USG revealed a significantly enlarged left ovary, positioned in the midline, characterised by a hyperechoic stroma. Within the ovary, there were small cysts of varying sizes, possibly representing follicles. Importantly, no internal blood flow was detected within the left ovary. These findings collectively suggest the likelihood of left ovarian torsion, a condition where the ovary twists on its axis, potentially compromising blood supply [Table/Fig-1].



[Table/Fig-1]: Ultrasonography (USG) findings.

The detorsion process involved a series of meticulous steps aimed at alleviating the torsional stress on the ovarian structure. Initiated through a carefully executed exploratory laparotomy, the surgical team identified the twisted left ovarian cyst along with any associated adhesions and ascites. Subsequently, the detorsion manoeuvre was

meticulously performed, requiring a delicate untwisting of the ovarian cyst to restore normal blood flow and prevent ischaemic damage. This procedure demanded precision to avoid potential complications and ensure the preservation of ovarian tissue viability. The success of the detorsion step set the stage for further surgical interventions, such as left ovarian cystectomy and bilateral salpingectomy, collectively contributing to a comprehensive approach in managing gynaecological conditions associated with ovarian torsion [Table/Fig-2]. Histopathological examination confirmed a benign serous cystadenoma. Two weeks post-surgery, the patient showed no complaints, with normal tumour markers, expressing satisfaction with the treatment and successful outcome of the surgical intervention.



[Table/Fig-2]: Intraoperative photograph of the tumour.

## DISCUSSION

Ovarian tumours, though diverse, can lead to rare yet critical complications such as torsion, wherein the ovary twists on its axis, compromising blood flow [1]. Ovarian torsion, though uncommon, poses a considerable risk, demanding inclusion in the differential diagnosis of abdominal pain, especially in women of reproductive age [2,3].

Ovarian cysts or masses can lead to ovarian torsion by twisting the utero-ovarian and infundibulopelvic ligaments, resulting in the tearing of the ovary [1,2]. Typically, these cysts or masses are benign and have a diameter exceeding 5 cm. Ovarian torsion primarily affects premenopausal women with elongated infundibulopelvic ligaments, although it can occur in women with normal ovaries [4]. Surgical cases of ovarian torsion show that 46% involved neoplasms and 48% involved cysts, with 89% of cases being benign [5,6]. This condition is more likely to occur in women of childbearing age. It may also affect healthy follicles, particularly in young individuals and those undergoing fertility treatments due to enlarged ovarian follicles [4]. Clinical presentation often includes lower abdominal or pelvic discomfort, which can vary in nature and may be accompanied by nausea and vomiting, particularly in children. Imaging, including USG and colour doppler studies, plays a crucial role in diagnosing ovarian torsion, especially for cysts measuring 8-12 cm or ovaries larger than 4 cm [5]. Delayed treatment can lead to complications such as ovarian necrosis, compromised fertility, stromal oedema, infarction of other structures, haemorrhage, infection and ovarian abscess [6-8]. Surgery, either laparoscopy or laparotomy, is the gold standard for treating ovarian torsion, focusing on preserving ovarian function through detorsion and sparing the ovary, whenever possible, even in cases where the ovary appears non viable based on visual examination during the operation [4].

Duan Y et al., reported three cases of ovarian torsion. An older woman with a history of hypertension, hyperlipidaemia and renal stones presented with sudden onset right lower quadrant pain. CT revealed an 8.8×6.3 cm mass in the left adnexa, and USG suggested ovarian torsion. A 32-year-old woman presented with menstrual-related nausea, revealing a 5 cm teratoma on USG and a 10.2 cm tumour on CT. Five days post laparoscopic torsion reduction, a 44-year-old woman presented with recurrent torsion symptoms, confirmed by imaging. All were managed with laparotomy and relieving the torsion [6]. Jeon H et al., reported a case in which a 65-year-old woman presented with lower left abdominal pain, worsening over three days. Radiological assessments revealed a 13×9 cm multicystic tumour in the left ovary. Computed tomography indicated a 16×9×14 cm multiseptated cystic mass, raising suspicion of malignancy. Exploratory laparotomy revealed a 17×9 cm cystic tumour with a 720° counterclockwise torsion in the left ovary. A frozen biopsy confirmed a borderline Brenner tumour associated with a benign mucinous tumour. Subsequent surgeries included left salpingo-oophorectomy, total hysterectomy and right salpingo-oophorectomy. No malignancy was detected in additional procedures, such as pelvic lymph node dissection [7].

Idris S et al., reported a case in which a 16-year-old girl presented with severe lower abdominal pain, vomiting and a history of similar episodes. Initially misdiagnosed with appendicitis, she was later referred to a gynaecologist. Examination revealed a movable mass, and USG indicated an 11×7 cm adnexal mass with a hyperechoic area and free fluid. Emergency laparotomy revealed a twisted, gangrenous left ovarian mass. Detorsion was attempted, but due to non viable tissue, a left salpingo-oophorectomy was performed [8].

Sandhu S et al., reported a case of 43-year-old woman who came to the Emergency Department with a rare acute presentation of bilateral

Krukenberg tumours due to unilateral ovarian torsion [9]. Mishra VV et al., reported a case of a 37-year-old woman with premature menopause who presented with persistent vomiting, escalating from mild to severe over 15 days. Previous conservative treatment for suspected food poisoning was ineffective. A non tender 5×5 cm cystic mass was palpable on examination through the left fornix. USG revealed a 6×4 cm cyst with internal septation and absent vascularity. Operative laparoscopy revealed a twisted, haemorrhagic 6×6 cm ovarian cyst, and a left salpingo-oophorectomy was performed. Postoperatively, she experienced symptom relief, and histopathology indicated a simple haemorrhagic ovarian cyst [10].

The present case report provides valuable insights into the clinical presentation, diagnostic challenges, and management strategies for ovarian tumour-related torsion. A multidisciplinary approach involving gynaecologists, radiologists, and surgeons is essential for optimal patient outcomes. By delving into the present case, the authors aimed to enhance medical knowledge, promote early detection, and stress the importance of swift intervention. This case serves as a reminder of the complexities involved in diagnosing and managing ovarian tumour-related torsion, emphasising the need for ongoing research and awareness in gynaecological medicine.

## CONCLUSION(S)

Identifying ovarian torsion can be demanding; a meticulous examination of the patient's symptoms, particularly the abrupt emergence of lower abdominal pain, is vital for its detection. Pelvic USG can furnish valuable insights into the presence of ovarian cysts. Surgical intervention becomes the primary approach for both diagnosis and treatment when ovarian torsion is suspected. Depending on the specific case, the preferred treatment options may include ovarian cystectomy, oophorectomy, or a conservative approach involving detorsion.

## REFERENCES

- McWilliams GDE, Hill MJ, Dietrich CS 3<sup>rd</sup>. Gynaecologic emergencies. Surg Clin North Am. 2008;88(2):265-83. vi. Doi: 10.1016/j.suc.2007.12.007.
- Robertson JJ, Long B, Koyfman A. Myths in the evaluation and management of ovarian torsion. J Emerg Med. 2017;52(4):449-56. Doi: 10.1016/j.jemermed.2016.11.012.
- Argenta PA, Yeagley TJ, Ott G, Sondheimer SJ. Torsion of the uterine adnexa. Pathologic correlations and current management trends. J Reprod Med. 2000;45(10):831-36.
- Huang C, Hong MK, Ding DC. A review of ovary torsion. Tzu-chi Med J. 2017;29(3):143-47. Doi: 10.4103/tcmj.tcmj\_55\_17.
- Albayram F, Hamper UM. Ovarian and adnexal torsion: Spectrum of sonographic findings with pathologic correlation. J ultrasound Med. 2001;20(10):1083-89. Doi: 10.7863/jum.2001.20.10.1083.
- Duan Y, Hoer B, Little A. Twisting ovaries: Three cases of ovarian torsion. Cureus. 2022;14(10):e30496. Doi: 10.7759/cureus.30496.
- Jeon H, Ryu A, Seo HG, Jang SH. Ovarian torsion of mixed epithelial tumour misdiagnosed as a malignancy in postmenopausal woman: A case report. Medicine (Baltimore). 2017;96(40):e8207. Doi:10.1097/MD.0000000000008207.
- Idris S, Daud S, Ahmad Sani N, Tee Mei Li S. A case of twisted ovarian cyst in a young patient and review of the literature. Am J Case Rep. 2021;22:e933438. Doi: 10.12659/AJCR.933438.
- Sandhu S, Arafat O, Patel H, Lall C. Krukenberg Tumour: A rare cause of ovarian torsion. J Clin Imaging Sci. 2012;2:6. Doi: 10.4103/2156-7514.93038.
- Mishra VV, Nanda S, Nawal R, Choudhary S. Unusual presentation of twisted ovarian cyst. J Midlife Health. 2016;7(1):31-33.

### PARTICULARS OF CONTRIBUTORS:

- Junior Resident, Department of Obstetrics and Gynaecology, NKP Salve Institute of Medical Sciences, Nagpur, Maharashtra, India.
- Associate Professor, Department of Obstetrics and Gynaecology, NKP Salve Institute of Medical Sciences, Nagpur, Maharashtra, India.

### NAME, ADDRESS, E-MAIL ID OF THE CORRESPONDING AUTHOR:

Dr. Varsha Kose,  
Associate Professor, Department of Obstetrics and Gynaecology, NKP Salve  
Institute of Medical Sciences, Nagpur-440016, Maharashtra, India.  
E-mail: deepakshigupta993@gmail.com; deepakshi2606@gmail.com

### AUTHOR DECLARATION:

- Financial or Other Competing Interests: None
- Was informed consent obtained from the subjects involved in the study? Yes
- For any images presented appropriate consent has been obtained from the subjects. Yes

### PLAGIARISM CHECKING METHODS: [Jan H et al.]

- Plagiarism X-checker: Sep 11, 2023
- Manual Googling: Feb 14, 2024
- iThenticate Software: Mar 04, 2024 (5%)

### ETYMOLOGY: Author Origin

EMENDATIONS: 6

Date of Submission: Sep 04, 2023

Date of Peer Review: Nov 01, 2023

Date of Acceptance: Mar 05, 2024

Date of Publishing: May 01, 2024